

## CEREBRAL OXIMETRY MONITORING DURING TRANSAPICAL AORTIC VALVE REPLACEMENT

J. Abicht<sup>1</sup>, C. Schmitz<sup>2</sup>, R. Sodian<sup>2</sup>, M. Wolf<sup>2</sup>, K. Nikolaou<sup>3</sup>, F. Christ<sup>1</sup>

<sup>1</sup>Klinik für Anaesthesiologie, Klinikum der Universität München

<sup>2</sup>Klinik und Poliklinik für Herzchirurgie, Klinikum der Universität München

<sup>3</sup>Institut für klinische Radiologie, Klinikum der Universität München

### INTRODUCTION:

The transapical aortic valve implantation (TAVI) is an established technique for high-risk patients requiring aortic valve replacement. In particular in patient older than 75 years the risk of cerebral injury after cardiac surgery is highly increased<sup>[1]</sup>.

During TAVI rapid ventricular pacing (rp) is required to enable precise positioning of the valve. These periods of reduced or suspended cardiac output may cause impaired organ perfusion and in particular hypoxemia of the brain. Transcranial cerebral oximetry (TCO) is a non-invasive method to detect cerebral hypoxia<sup>[2,3]</sup>.

### METHODS:

From 10/2009 to 01/2010 TCO was used in 12 patients scheduled for TAVI (Table 1). TCO [EQUANOX 7600, Nonin Medical, Plymouth MN, USA] was established as a routine monitoring in TAVI to monitor the impact of rapid pacing on cerebral oxygenation. Regional oxygen saturation (rSO<sub>2</sub>) of both frontal lobes as well as hemodynamic data were recorded continuously throughout the operation.

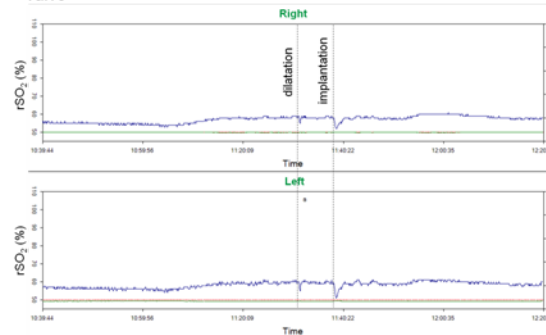
### RESULTS:

The quality of signal acquisition was excellent throughout the operation. During rapid pacing of duration longer than 5 seconds a bilateral decrease of cerebral oxygenation was apparent in all patients (Figure). rSO<sub>2</sub>% values never decreased by more than 6% and in all patients a normalisation to baseline was observed within 120 seconds (Table 2). In all patients monitored with TCO, no neurologic complications were detected postoperatively.

**Table 1** Data of last twelve patients that received TAVI

	TAVI (n = 12)
<b>demographic data</b>	
gender (female)	7 (58%)
age (years)	78 [59-87]
<b>perioperative risk and clinical data</b>	
STS score	31 ± 11
log. EuroSCORE	23 ± 10
<b>outcome</b>	
stroke	-
death	-

**Figure:** rSO<sub>2</sub> (%) during TAVI with two sequences of rapid pacing during dilatation of the old aortic valve and implantation of the new valve



**Table 2:** hemodynamic and cerebral oxygenation during rapid pacing

	dilatation	implantation
<b>rapid pacing (rp)</b>		
rate of rp (1/min)	180	180
duration of rp (s)	13 ± 3	21 ± 4
<b>hemodynamic</b>		
MAP before rp (mmHg)	75 ± 13	74 ± 10
Δ MAP after rp (mmHg)	-20 ± 12	-19 ± 18
NE before rp (mg/h)	0.33 ± 0.18	-
NE 5 min after rp (mmHg)	-	0.35 ± 0.16
<b>cerebral oxygenation</b>		
max. drop of rSO <sub>2</sub> %	3.5 ± 1.7	3.5 ± 2.1
time to recover	49 ± 48	54 ± 37

MAP = mean arterial blood pressure, NE = Norepinephrine

### CONCLUSION:

rSO<sub>2</sub> recovered fast after all sequences of rapid pacing during aortic valve implantation. Monitoring of cerebral oxygenation may provide more safety to the patient during this procedure.

### REFERENCES:

- [1] Ahonen J, Salmenperä M. Brain injury after adult cardiac surgery. Acta Anaesthesiol Scand 2004;48:4-19.
- [2] Smythe PR, Samra SK. Monitors of cerebral oxygenation. Anesthesiol Clin North America 2002;20:293-313.
- [3] Muehlschlegel S, Lobato EB. Con: all cardiac surgical patients should not have intraoperative cerebral oxygenation monitoring. J Cardiothorac Vasc Anesth 2006;20:613-5.